Downloaded from www.ajronline.org by 141.6.11.24 on 02/08/17 from IP address 141.6.11.24. Copyright ARRS. For personal use only; all rights reserved

BASF DocID 1997/1008681

Pictorial Essay

The Aberrant Subclavian Artery

Kelly Freed[1] and Vincent H. S. Low

An aberrant subclavian artery and related anomalous vascular structures are not infrequent findings on imaging obtained for unrelated reasons. This pictorial essay presents the imaging appearance of these findings using the various techniques available. We also discuss the clinically important variants of these anomalies that warrant further intervention.

Materials and Methods

During the last 6 years we have retrospectively identified 32 patients with aberrant subclavian arteries and related vascular rings. Twenty-seven patients had a left-sided aortic arch with an aberrant right subclavian artery (ARSA), whereas four had a right-sided aortic arch with an aberrant left subclavian artery. All these patients were asymptomatic. Aneurysm of an ARSA was seen in one patient. One patient had a double aortic arch and dysphagia.

Twenty-one of the subjects were female, and 11 were male. They ranged in age from 5 months to 75 years old (mean age, 54 years old). Barium esophagography was performed in 13 patients, CT in 20, MR imaging in two, and conventional angiography in three.

Discussion

The ARSA was first described on necropsy by Hunauld in 1735. In 1787, David Bayford, before the Medical Society of London, used the term "dysphagia lusoria," or "difficulty in swallowing due to a quirk of nature," in describing symptoms related to this anomaly. The radiologic findings were first described in 1936 by Kommerell, and surgical management of the problem was discussed by Gross in 1946 [1].

The ARSA is the most common of the intrathoracic major arterial anomalies, with an incidence of 0.4–2%. In this anomaly, the ARSA arises as the last great vessel of the aortic arch. The anomaly occurs as a result of interruption between the right common carotid artery and the ARSA in the developing double aortic arch. Normal embryonic development of the aortic arch and great vessels begins as six paired ventral and dorsal arches [1]. Certain segments disappear, and others persist during development of the fetus. The left fourth arch forms the aortic arch. The right fourth arch contributes to the formation of the right subclavian artery, as does the seventh intersegmental artery. In the ARSA, the right fourth arch and proximal right dorsal aorta involute, and the right seventh intersegmental artery develops from a persistent dorsal aorta [1]. An aortic diverticulum may be present at the origin of this vessel, representing the remnant of the distal right aortic arch. The ARSA arises from the dorsal margin of the aorta. It then passes behind the esophagus (Figs. 1–5) in almost all cases; indeed, passage of the ARSA in front of the esophagus or trachea occurs rarely if ever [2]. An aberrant left subclavian artery arising from a right aortic arch is far less common, occurring in one in 1000 people.

Most patients with ARSA are asymptomatic, and the anomaly is found incidentally, either by radiography or endoscopy. Rarely, this malformation has been suspected as the cause of dysphagia. Pediatric patients may present with respiratory compromise due to tracheal compression. In adults, the trachea is more resistant to compression. An aneurysmal aberrant subclavian artery may present as a superior mediastinal mass.

On barium esophagography, the ARSA consistently produces a characteristic oblique fron-

Received January 29, 1996; accepted after revision July 25, 1996.

[1]Both authors: Department of Radiology, Duke University Medical Center, Box 3808—Hospital South, Durham, NC 27710. Address correspondence to V. H. S. Low.

AJR 1997;168:481–484 0361–803X/97/1682–481 © American Roentgen Ray Society

Downloaded from www.ajronline.org by 141.6.11.24 on 02/08/17 from IP address 141.6.11.24. Copyright ARRS. For personal use only; all rights reserved

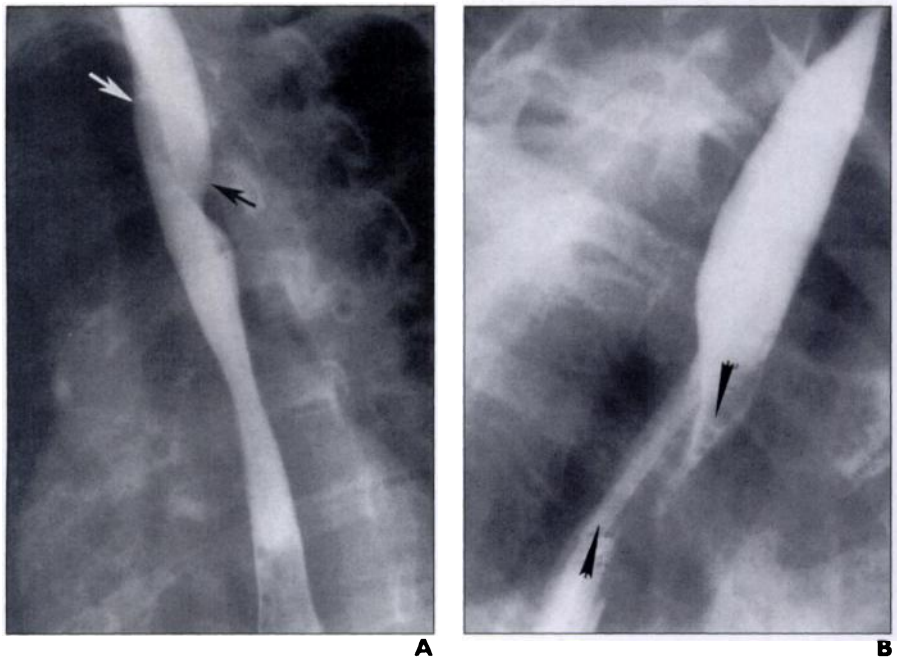

Fig. 1.—23-year-old woman with aberrant right subclavian artery (ARSA).
A, Left anterior oblique (LAO) view of barium esophagogram shows characteristic posterolateral oblique extrinsic compression on esophagus. Impression (*arrows*) passes cephalad from region of aortic arch toward medial head of right clavicle. This LAO view consistently showed this indentation in all patients with ARSA.
B, Right anterior oblique view of barium esophagogram reveals impression similar to that seen in **A**. Detailed view shows normal mucosa. Transmitted pulsations were seen fluoroscopically (not shown). Note simultaneous displacement of esophagus immediately superior and inferior to ARSA. Displacement produces bayonet deformity (*arrows*).

Fig. 2.—59-year-old woman with aberrant left subclavian artery. Left anterior oblique view of barium esophagogram shows nonspecific simple extrinsic indentation on supraaortic esophagus.

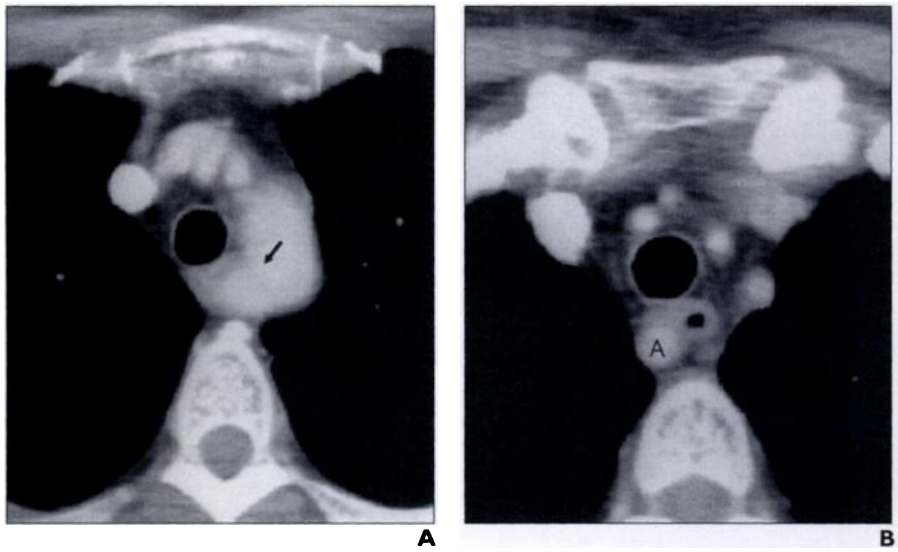

Fig. 3.—53-year-old woman with aberrant right subclavian artery (ARSA).
A, IV contrast–enhanced CT scan at level of aortic arch reveals ARSA (*arrow*) budding to right of distal arch.
B, Enhanced CT scan of chest taken 2 cm cephalad to **A** shows ARSA (A) passing posterior to esophagus. Such course was taken by aberrant vessel in all 20 of our patients studied by CT.

tal and lateral supraaortic impression on the left anterior oblique view. The opposite (right anterior) oblique view did not consistently reveal this typical deformity in all our patients with ARSA but instead appeared as a nonspecific simple impression. Differential diagnoses of such a nonspecific impression include mediastinal lymphadenopathy, other tumors or masses (such as duplication cysts), or other vascular structures. The diagnostic difficulty of this nonspecific appearance can be avoided by always studying the esophagus in both oblique views. Conversely, the right anterior view did show the characteristic contour in all our patients with an aberrant left subclavian artery.

Cross-sectional imaging, such as CT and MR imaging, will show the relationship of the various mediastinal vessels and structures with-

Downloaded from www.ajronline.org by 141.6.11.24 on 02/08/17 from IP address 141.6.11.24. Copyright ARRS. For personal use only; all rights reserved

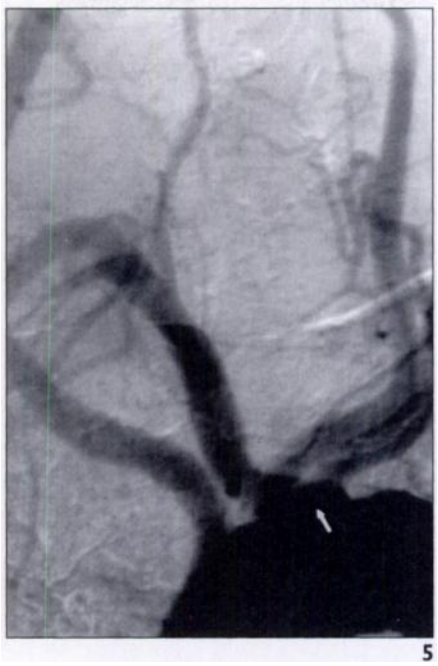

Fig. 4.—29-year-old woman with aberrant right subclavian artery. Unenhanced T1-weighted spin-echo MR sagittal image shows bayonet deformity of esophagus (*arrows*) in relation to aberrant vessel (A) passing posteriorly.

Fig. 5.—67-year-old woman with aberrant right subclavian artery. Anteroposterior digital subtraction view of catheter arch aortogram shows aberrant vessel (*arrow*) as most distal branch of aortic arch.

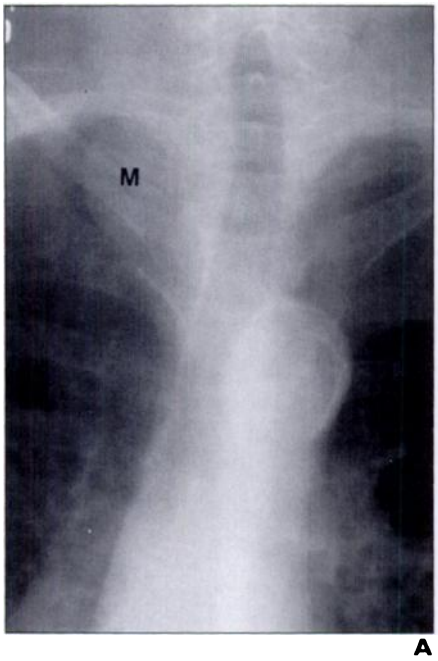

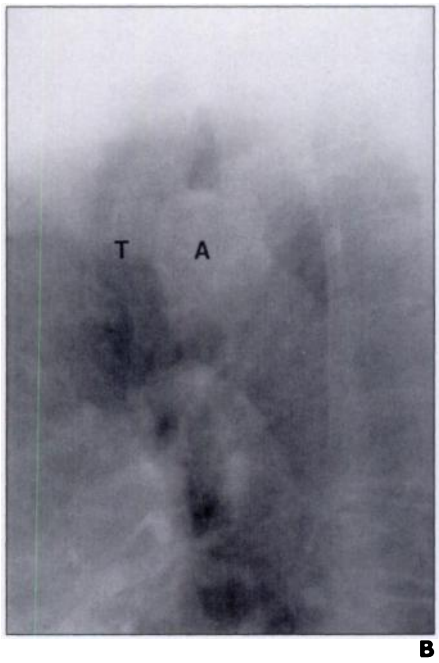

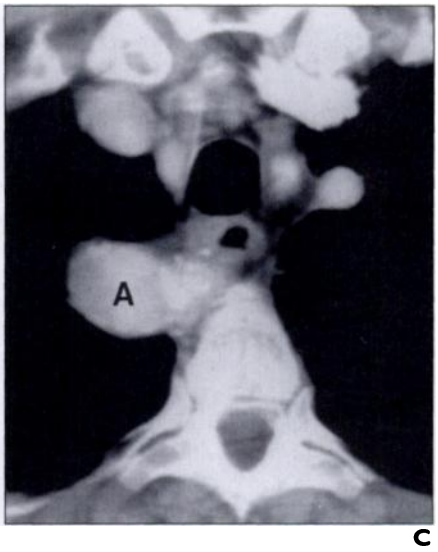

Fig. 6.—70-year-old woman with aneurysm of aberrant right subclavian artery (ARSA).
A, Frontal chest radiograph depicts aneurysmal ARSA as superior mediastinal mass (M).
B, Lateral chest radiograph shows anterior bowing of trachea (T) by aneurysm (A).
C, IV contrast-enhanced CT scan at level of sternal notch shows 3-cm aneurysm (A) of proximal ARSA. Note mural calcification and asymmetric thrombus.

out the need for conventional catheter angiography. In asymptomatic patients, these findings are diagnostic of an aberrant subclavian artery and require no additional workup. In the absence of symptoms, the nonaneurysmal aberrant subclavian artery is a normal variant, unassociated with intracardiac defects, and requires no further evaluation or treatment.

Aneurysmal dilatation of the proximal portion of the ARSA is not extremely rare, occurring in 8% of cases [3]. In our series of 32 patients, only one (3%) had aneurysmal dilatation of the proximal aberrant vessel (Fig. 6). Such an aneurysm may or may not be associated with Kommerell's diverticulum and is believed to be the result of arteriosclerotic disease [4]. These lesions are usually found incidentally as a mediastinal mass on chest

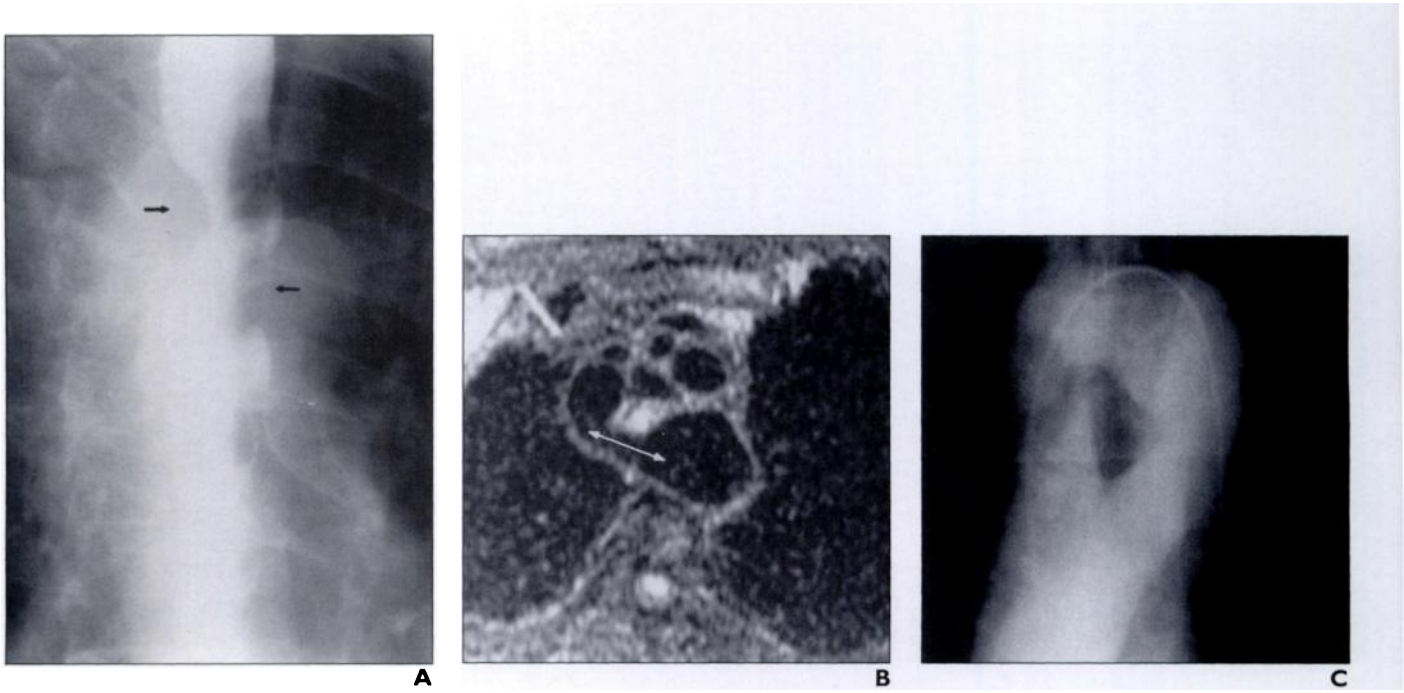

Fig. 7.—67-year-old man with double aortic arch. He had progressive dysphagia.
A, Barium swallow shows staggered bilateral extrinsic indentations (*arrows*) on supraaortic esophagus.
B, T1-weighted axial MR image shows retroesophageal connection (*arrow*) between larger left aortic arch and patent right aortic arch.
C, Conventional catheter aortogram shows divergence of arch. After this patient underwent surgical division of double aortic arch, his symptoms improved.

radiographs or CT scans. They can be specifically diagnosed by contrast-enhanced CT or MR imaging. About half the cases of aneurysmal aberrant subclavian artery reported in the literature have ruptured with conservative management, prompting some authors to recommend surgery even in asymptomatic patients [5].

Dysphagia is an unusual result of an aberrant subclavian artery. When dysphagia does occur, it suggests the presence of an additional anomaly resulting in a complete vascular ring. Such anomalies include ductus arteriosus or an abnormal origin of the carotid arteries, effectively encircling the esophagus [2]. Our one symptomatic patient had a vascular ring created by a double aortic arch (Fig. 7).

The aneurysmal aberrant subclavian artery or symptomatic vascular ring warrants further imaging assessment before surgery. CT with IV contrast enhancement reveals mediastinal relationships. MR imaging is the single best technique to show the relationship of the anomalous vessels to the other mediastinal structures. Axial MR images will reproduce findings on CT scans. The orthogonal views available on MR imaging will elegantly show the relationship of the aberrant vessel to the esophagus along its long axis. MR imaging also has the advantages of multiplanar representation, no radiation exposure, and no need for contrast infusion. MR angiography would be useful to illustrate the vascular relationships.

References

1. Felson B, Cohen S, Courter SR, McGuire J. Anomalous right subclavian artery. *Radiology* **1950**;54:340–349
2. Klinkhamer AC. Aberrant right subclavian artery: clinical and roentgenologic aspects. *AJR* **1966**;97:438–446
3. Branscom JJ, Austin JHM. Aberrant right subclavian artery: findings seen on plain chest roentgenograms. *AJR* **1973**;119:539–542
4. Turkenburg JL, Versteegh MIM, Shaw PC. Case report: aneurysm of an aberrant right subclavian artery diagnosed with MR imaging. *Clin Radiol* **1994**;49:837–839
5. Akers DL, Fowl RJ, Plettner J, Kempczinski RF. Complications of anomalous origin of the right subclavian artery: case report and review of literature. *Ann Vasc Surg* **1991**;5:385–388

Downloaded from www.ajronline.org by 141.6.11.24 on 02/08/17 from IP address 141.6.11.24. Copyright ARRS. For personal use only; all rights reserved