Toxicology, 41 (1986) 213 — 231
Elsevier Scientific Publishers Ireland Ltd.

INHALATION TOXICITY OF ACETALDEHYDE IN RATS. III. CARCINOGENICITY STUDY*

R.A. WOUTERSEN, L.M. APPELMAN, A. VAN GARDEREN-HOETMER and V.J. FERON
TNO-CIVO Toxicology and Nutrition Institute, Zeist (The Netherlands)

(Received October 14th, 1985)
(Accepted April 7th, 1986)

SUMMARY

Male and female Wistar rats were exposed to acetaldehyde vapour at nominal concentrations of 0, 750, 1500 or 3000/1000 ppm during 6 h/day, 5 days/week for up to 28 months. Major compound-related effects included increased mortality, growth retardation, nasal tumours, and non-neoplastic nasal changes in each of the test groups. The treatment-related nasal changes comprised: (1) degeneration, hyperplasia, metaplasia and adenocarcinomas of the olfactory epithelium at all exposure levels; (2) squamous metaplasia accompanied by slight to severe keratinisation and squamous cell carcinomas of the respiratory epithelium at the 2 highest exposure levels; and (3) slight to severe rhinitis and sinusitis in top-concentration rats. In the larynx hyperplasia and keratinized squamous metaplasia of the epithelium in the vocal cord region were seen in many rats of the mid- and top-concentration groups. One female rat of the 1500 ppm group had developed a laryngeal carcinoma in situ. It was concluded that under the conditions of the present study acetaldehyde is both cytotoxic and carcinogenic to the nasal mucosa of rats. The effects of acetaldehyde on the nose were compared to those of formaldehyde.

Key words: Acetaldehyde; Inhalation; Carcinogenicity; Rats

INTRODUCTION

Acetaldehyde is used in the manufacture of synthetic chemicals, as a solvent in the rubber, tanning and paper industries, and is one of the major irri-

* Supported by: (1) Ministry of Housing, Physical Planning and Environmental Protection, Leidschendam, The Netherlands (2) The "Stichting Koningin Wilhelmina Fonds", Netherlands Cancer Foundation, Amsterdam, The Netherlands (3) TNO-CIVO Toxicology and Nutrition Institute, Zeist, The Netherlands.
Address all correspondence to: Dr R.A. Woutersen, TNO-CIVO Toxicology and Nutrition Institute, P.O. Box 360, 3700 AJ Zeist, The Netherlands.

0300-483X/86/$03.50
© 1986 Elsevier Scientific Publishers Ireland Ltd.
Printed and Published in Ireland

tants of the vapour phase of tobacco smoke [1—4]. From short- and long-term inhalation studies in hamsters it appeared that this aldehyde at concentrations of 1500 ppm and higher is capable of inducing inflammatory changes and severe hyper- and metaplasia of the epithelium in the upper parts of the respiratory tract, and also of inducing tumours of the laryngeal and nasal epithelium [5—7]. This finding seems of particular interest in view of the data on the occurrence of carcinomas in the nose of rats and mice following exposure to formaldehyde vapour [8—11]. To verify the findings with acetaldehyde in hamsters and to put the data on formaldehyde in a wider perspective, short- and long-term inhalation studies including a recovery experiment have been carried out with acetaldehyde in rats. The short-term studies in rats again showed that the nose and larynx were the main target sites for this compound [12]. This finding was fully confirmed by the results obtained during the first 15 months of a life-span study in rats using levels of 0, 750, 1500, or 3000/1000 ppm [13]. At the end of the 15-month test period it was already clear that exposure of rats to acetaldehyde resulted in nasal carcinomas at each of the concentration levels. The present paper presents the final results of the 28-month carcinogenicity study.

MATERIALS AND METHODS

Test substance and inhalation equipment

For details on acetaldehyde, the inhalation chambers and the methods used for generating, monitoring and analyzing the test atmospheres, the reader is referred to a previous publication [12].

Treatments

Four hundred and twenty male and 420 female rats (Cpb:WU, Wistar random), 6 weeks of age, were assigned to 4 groups of 105 males and 105 females each, by computer randomisation. The rats in the different groups were exposed to atmospheres containing acetaldehyde at levels of 0, 750, 1500 or 3000/1000 ppm, respectively, for 6 h/day, 5 days/week. Each group was divided into 5 subgroups:

Subgroup (code)	Treatment (test) period	No. of rats	
		M	F
1	13 weeks	5	5
2	26 weeks	5	5
3	12 months	10	10
4	12 months[a]	30	30
5	28 months	55	55

[a] Treatment period was followed by a recovery period of up to 12 months.

The results obtained after 13, 26 and 52 weeks, including haematology, serum chemistry and urinalysis, have been published previously [13]. The recovery study will be the subject of a separate paper.

Housing conditions

All animals were housed in the inhalation chambers, 5 males or 5 females/cage, both during and after the exposures. Neither food nor drinking water was present in the inhalation chambers during the exposures. During the non-exposure periods the rats were provided ad libitum with bottled tap water and the Institute's stock diet for rats.

Conduct of the study

The general condition and behaviour of the rats were checked daily and body weights were recorded weekly during the first month, bi-weekly during the next 2 months and monthly thereafter. At termination of the study in weeks 120—122, the survivors of subgroup 5 were killed and autopsied. All rats found dead or killed in extremis during the course of the study were also autopsied and subjected to detailed macroscopic examination. Samples of a wide range of tissues and organs including the nose, larynx, trachea with main bronchi and lungs were fixed in formalin, processed through paraffin wax, sectioned at 5 μm, stained with haematoxylin and eosin and examined by light-microscopy.

Statistical analysis

Analysis of co-variance was carried out on the body weights to adjust for differences in initial body weight. The Dunnett's test was used for comparing the adjusted group means. For histopathological changes, the Fisher exact probability test or the chi-square test with continuity correction was used.

RESULTS

Exposure levels

The mean analytical concentrations of acetaldehyde to which the rats in the different groups were exposed during the study were 0, 735 and 1412 ppm for the control, low- and mid-concentration group, respectively, and for the top-concentration group 3033 ppm from day 0 to 141; 2167 ppm from day 142 to 210; 2039 ppm from day 211 to 238; 1433 ppm from day 239 to 300; 1695 ppm from day 301 to 312; 1472 ppm from day 313 to 359, and 977 ppm thereafter. The highest concentration was gradually decreased because of severe growth retardation, occasional loss of body weight and early mortality in this group.

Symptomatology

The animals of the top-concentration group showed excessive salivation, laboured respiration, and mouth breathing. The acetaldehyde concentration was gradually reduced from 3000 to 1000 ppm in the course of the first 52 weeks. The respiratory distress was still observed after the exposure concentration had been lowered, although fewer dyspnoeic animals were seen each time after lowering the exposure level. In the course of month 12, several top-concentration animals showed blood around their nares. Despite a further reduction of the acetaldehyde concentration to about 1000 ppm, the number of

animals showing this condition increased after 12 months. During the study most animals of the 2 highest concentration groups and a few animals of the low-concentration group showed yellowing of the fur.

In month 12, one male top-concentration rat showed a nasal swelling. Thereafter, many rats of the various treatment groups developed rapidly expanding nasal swellings, which invariably appeared to be caused by nasal carcinomas.

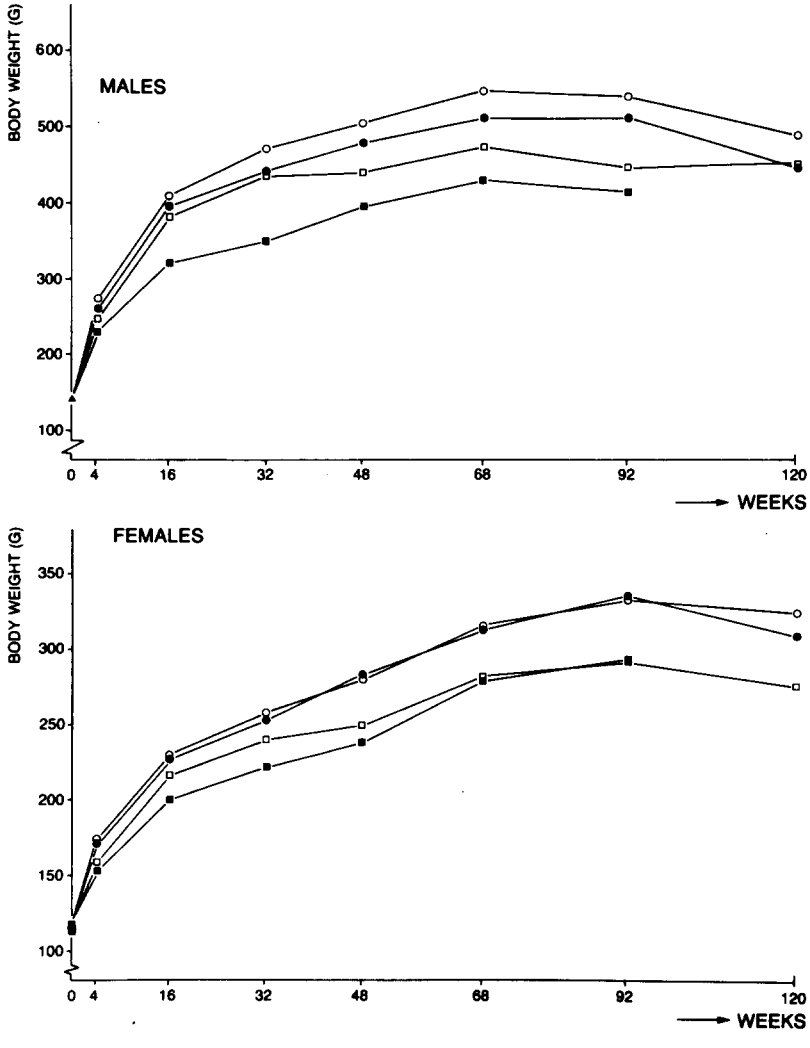

Fig. 1. Growth curves of rats exposed to acetaldehyde vapour for up to 28 months. Control (-O-), low-concentration (- ● -), mid-concentration (-□-), and top-concentration (-■-) animals.

Body weights and mortality

Growth retardation occurred in males of each test group and in females of the 2 highest concentration groups; there was a clear, positive dose-effect relationship (Fig. 1). Only a few rats died or were killed in extremis during the first 6 months of the study. Thereafter, a sharp increase in the number of deaths occurred in the top-exposure group. At day 468, the mortality rate in the top-concentration group was 50% (28/55) for males and 42% (23/55) for females. By day 715, all top-concentration rats had died. When the study was terminated at day 844, in the mid-concentration group only a few animals were still alive (Fig. 2).

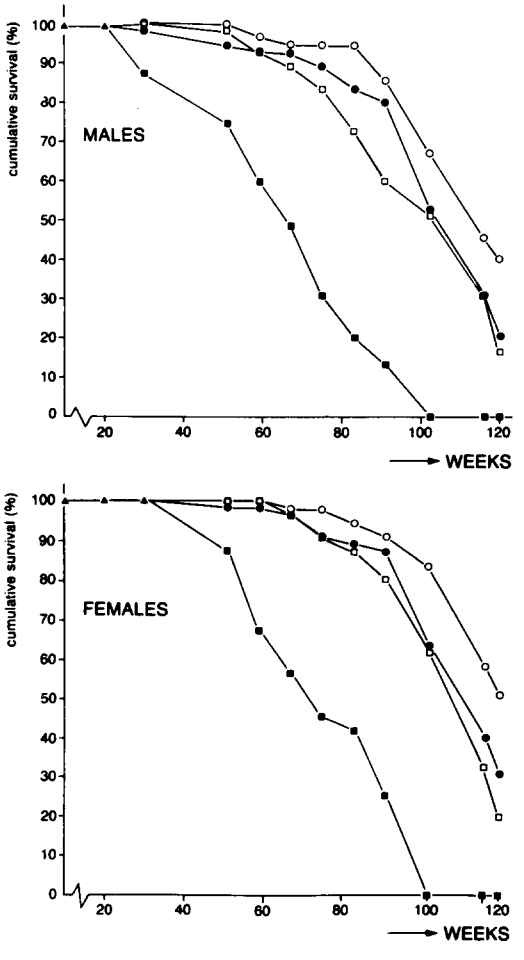

Fig. 2. Cumulative survival of rats exposed to acetaldehyde vapour for up to 28 months. Control (-O-), low-concentration (- ● -), mid-concentration (-□-), and top-concentration (-■-) animals.

Pathology

Gross examination. Gross examination at autopsy did not reveal treatment-related changes except for a yellowish-brown discolouration of the fur of most animals of the mid- and top-concentration groups and of a few animals of the low-concentration group, and nasal swellings in all test groups and in 1 control animal. A deformed nose due to a focal swelling suggestive of a neoplastic process in the nasal cavity was observed in 5 males and 9 females of the top-exposure group, 6 males and 8 females of the mid-exposure group, 6 males and 3 females of the low-exposure group, and also in 1 male control animal. The swellings varied in size from small thickenings just visible with the naked eye to large protrusions measuring up to 3 x 3 x 2 cm. They consisted of yellowish or greyish-white, soft to fairly firm tissue masses, which eroded through the nasal bones and invaded the subcutis. In some cases the tissue mass was seen to extend into the brain. The latter condition was found in animals with or without a nasal swelling, viz. in 7 low-concentration, 21 mid-concentration and 10 top-concentration rats.

Many gross lesions were age-associated and occurred to a lower incidence in the top-concentration group than in the other groups including the controls, due to the relatively early mortality in the top-concentration group. There was no indication that any of the grossly visible lesions, except for the discolouration of the fur and the nasal swellings, was related to acetaldehyde exposure.

Microscopic examination. The cause of early death or moribund condition of top-concentration rats was nearly always partial or complete occlusion of the nose by excessive amounts of keratin and inflammatory exudate. Several male and female top-concentration rats that died or were killed in moribund condition showed acute bronchopneumonia occasionally accompanied by tracheitis. In nearly all the affected animals, feed particles were found in the tracheo-bronchial tree. Moreover, the nose of each of these rats was partially or completely occluded by a nasal tumour or a plug of keratin with or without inflammatory exudate. One might speculate that rats being obligatory nose breathers easily inhale feed particles in attempts to breath through the mouth.

Compound-related histopathological changes were found in the nose and larynx. The most severe abnormalities were found in the nose at each of the exposure levels; there was a clear, positive dose-response relationship (Table I). Laryngeal lesions were found in the top-exposure group only.

Squamous metaplasia accompanied by slight to very severe keratinisation of the nasal respiratory epithelium was found in most animals of the mid- and top-concentration groups. Keratinisation was most severe in top-concentration animals (Table I). Hyperplasia of the respiratory epithelium was observed in several mid-concentration rats and in a few top-concentration rats. In low-concentration rats, the respiratory epithelium was hardly affected.

A few animals of the top- and mid-concentration groups showed focal squamous metaplasia with or without keratinisation of the olfactory epithelium. Basal cell hyperplasia of the olfactory epithelium was seen in low- and mid-concentration rats. In the mid-concentration group, the hyperplastic cells were often atypical and nests of such cells were frequently found in the

TABLE 1

SITE, TYPE AND INCIDENCE OF TREATMENT-RELATED NON-NEOPLASTIC EPITHELIAL CHANGES IN THE RESPIRATORY TRACT OF RATS EXPOSED TO VARIOUS CONCENTRATIONS OF ACETALDEHYDE VAPOUR FOR AT MOST 28 MONTHS

Site and type of lesions	Incidence of lesions [a]							
	Males, conc. group				Females, conc. group			
	Control	Low	Mid	Top	Control	Low	Mid	Top
Nose	(49)	(52)	(53)	(49)	(50)	(48)	(53)	(53)
Squamous metaplasia of respiratory epithelium								
a. without keratinisation	0	1	11**	1	0	3	14***	0
b. with keratinisation	0	0	5	19***	0	1	16***	18***
Papillomatous hyperplasia of respiratory epithelium	0	0	0	2	0	0	0	6*
(Focal) simple or pseudo-epitheliomatous hyperplasia of respiratory epithelium	0	5	16***	8**	0	3	31***	9**
Focal squamous metaplasia of olfactory epithelium								
a. without keratinisation	0	0	0	0	0	0	1	1
b. with keratinisation	0	0	0	3	0	0	0	0
(Focal) basal cell hyperplasia of olfactory epithelium								
a. without atypia	0	37***	9**	0	0	42***	19***	0
b. with atypia	0	1	17***	0	0	0	5	0
Focal aggregates of (atypical) basal cells in the submucosa beneath the olfactory epithelium	0	0	23***	0	0	0	31***	2
Focal proliferation of glands in the thickened submucosa of the olfactory epithelium	0	0	14***	5	0	4	18***	5
Larynx	(50)	(50)	(51)	(47)	(51)	(46)	(47)	(49)
Squamous metaplasia/ hyperplasia								
a. without keratinisation	2	2	10*	9*	1	0	6	9*
b. with keratinisation	1	4	13**	32***	0	3	17***	23***
Proliferation of dysplastic epithelium	0	0	1	0	0	1	4	2

(Continued)

TABLE I *(Continued)*

Site and type of lesions	Incidence of lesions [a]							
	Males, conc. group				Females, conc. group			
	Control	Low	Mid	Top	Control	Low	Mid	Top
Lungs	(55)	(54)	(55)	(52)	(53)	(52)	(54)	(54)
Keratinized stratified squamous metaplasia of bronchial epithelium	0	0	0	1	0	0	0	0

[a] The number of animals examined is given in brackets.
Statistics: Fisher Exact Test $^{*}P < 0.05$, $^{**}P < 0.01$, $^{***}P < 0.001$.

submucosa. In some cases these nests appeared to be submucosal extensions of a nasal adenocarcinoma located more caudally. Basal cell hyperplasia of the olfactory epithelium was not found in animals of the top-concentration group. This observation seems most probably due to early death of the animals caused by squamous cell carcinoma originating from the respiratory epithelium or to the rapid development of adenocarcinoma from the severely injured olfactory epithelium. Several mid-concentration animals showed hyperplasia of gland-like structures in the increased amount of loosely arranged connective tissue of the submucosa beneath the olfactory epithelium (Table I).

In the vocal cord region of the larynx slight hyperplasia and squamous metaplasia of the epithelium occasionally accompanied by keratinisation was found in most male and female rats of the mid- and top-concentration groups. A few animals showed extensive metaplasia with severe keratinisation in the laryngeotracheal region (Table I). The tracheal epithelium was not visibly affected by acetaldehyde.

In the nose, 2 different types of malignant nasal tumours were found: squamous cell carcinomas and adenocarcinomas (Table II). Squamous cell carcinomas and carcinomas in situ were mainly found in animals of the mid- and top-concentration group, and their incidence increased with increasing concentration (Table II). In addition, 1 male animal of the control group and 1 male of the low-concentration group also developed a nasal squamous cell carcinoma. Both animals had severe necrotizing rhinitis, odontodystrophy and periodontitis and the tumour was located in one side of the nose around a dystrophic incisor tooth. The squamous cell carcinomas varied from large tumours (Fig. 3) filling one or both sides of the nasal cavity, destroying turbinates, invading the nasal bones and extending into the subcutis and brain to small neoplastic processes infiltrating the submucosa of the nasal epithelium. The origin of the large squamous cell carcinomas could not be determined; the small tumours were seen to originate from metaplastic keratinized stratified squamous respiratory epithelium located in the more anterior part of the nasal cavity. Some

TABLE II

SITE, TYPE AND INCIDENCE OF RESPIRATORY TRACT TUMOURS IN RATS EXPOSED TO VARIOUS CONCENTRATIONS OF ACETALDEHYDE VAPOUR FOR AT MOST 28 MONTHS

Site and type of tumours	Incidence of tumours [a]							
	Males, conc. group				Females, conc. group			
	Control	Low	Mid	Top	Control	Low	Mid	Top
Nose	(49)	(52)	(53)	(49)	(50)	(48)	(53)	(53)
Papilloma	0	0	0	0	0	1	0	0
Squamous cell carcinoma	1	1	10*	15***	0	0	5	17***
Carcinoma in situ	0	0	0	1	0	0	3	5
Adenocarcinoma	0	16***	31***	21***	0	6*	26***	21***
Larynx	(50)	(50)	(51)	(47)	(51)	(46)	(47)	(49)
Carcinoma in situ	0	0	0	0	0	0	1	0
Lungs	(55)	(54)	(55)	(52)	(53)	(52)	(54)	(54)
Poorly differentiated adenocarcinoma	0	0	0	0	0	1	0	0

[a] The number of animals examined is given in brackets.
Statistics: Fisher Exact Test $^{*}P < 0.05$, $^{**}P < 0.01$ $^{***}P < 0.001$.

squamous cell carcinomas, however, were found to originate from metaplastic, keratinized squamous olfactory epithelium located in the dorsomedial and more posterior part of the nose.

Adenocarcinomas were found in each of the test groups (Table II). The incidence of this tumour was highest in the 1500 ppm group, in both males and females; in the low-concentration group the incidence was higher in males than in females. The adenocarcinomas varied in size from small nests of atypical cells present in the submucosa of the olfactory epithelium, which grew along the structures of the nasal cavity and only invaded some nerve bundles (Fig. 4), to large osteolytic tumours growing outside the nose into the subcutis and frequently invading the cerebrum via the olfactory lobe (Figs. 5 and 6). Mitotic activity was high, especially in those tumours which exhibited osteolytic activity and local invasion, destroying the cribriform plate of the skull and invading the cerebrum. Most of these tumours consisted of sheets or cords of densely packed cells with little basophilic cytoplasm and large hyperchromatic nuclei with often 1 or 2 big nucleoli. In addition to this type of adenocarcinomas, 'adenocarcinomas' were observed consisting of masses of cells having scant cytoplasm and large, round to ovoid nuclei with prominent chromatin. They were divided into lobules by fibrovascular septae. Some tumours exhibited rosettes, pseudorosettes, palisading or glandular formations suggesting a neurogenic origin (esthesioneuroepitheliomas?) (Fig. 7). The olfactory epithelium is considered the site of origin of both types of nasal adenocarcinomas.

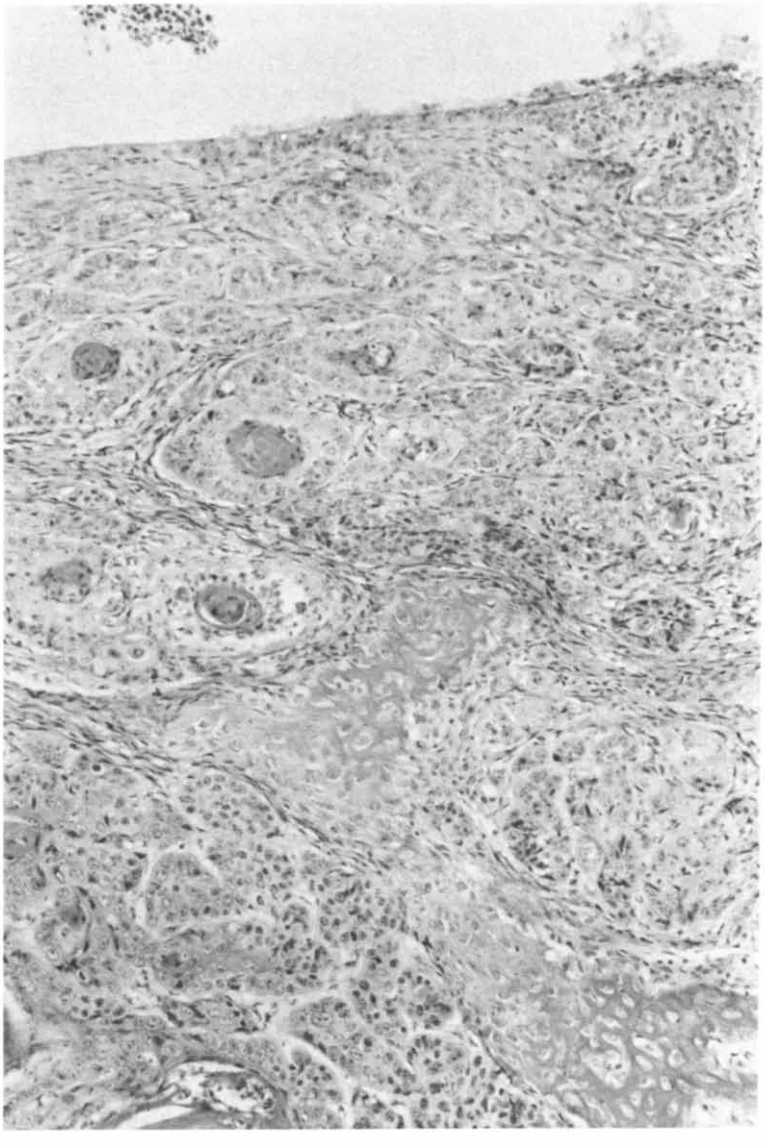

Fig. 3. Squamous cell carcinoma filling one side of the nasal cavity and destroying nasal turbinates (female mid-concentration animal, H&E, x 200).

Table III shows that the earliest nasal tumours were not only found in top-concentration rats but also in low- and mid-concentration rats, suggesting that the latency period of nasal tumours was independent of the acetaldehyde exposure concentration. This was more evident for adenocarcinomas than for squamous cell carcinomas.

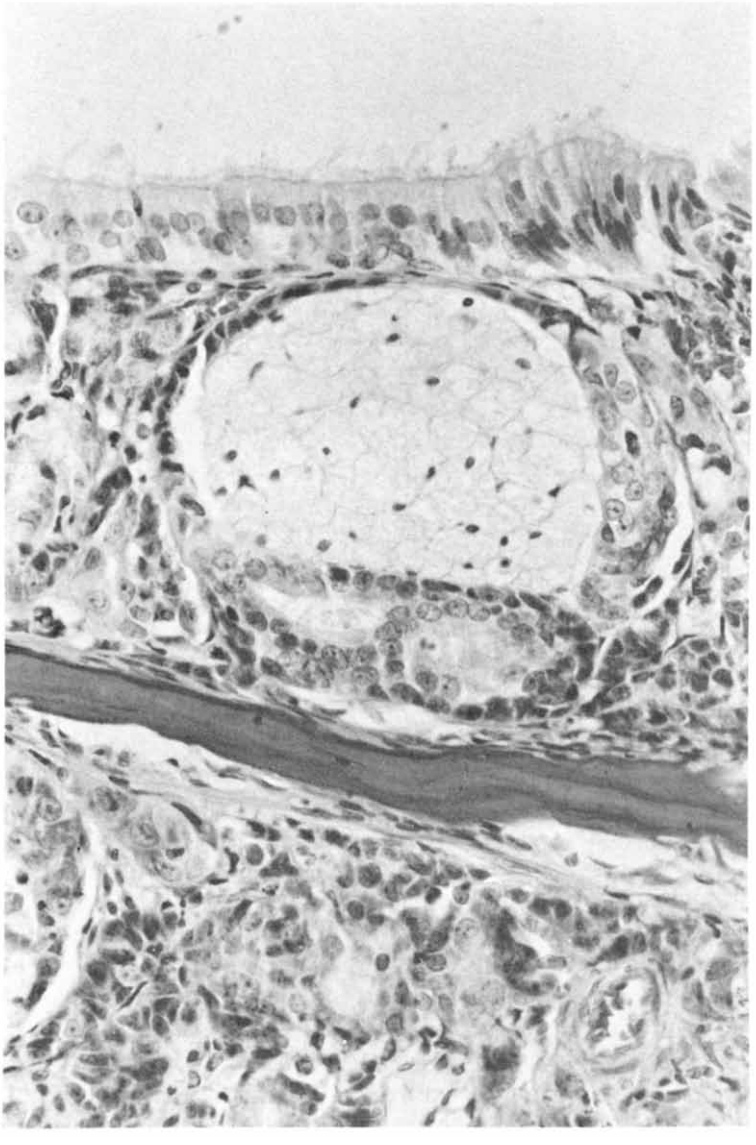

Fig. 4. Adenocarcinoma of the nasal olfactory epithelium. Tumour cells are seen to infiltrate a nerve bundle. Note the absence of sensory cells in the olfactory epithelium, which resembles respiratory epithelium, but most probably consists of sustentacular cells and basal cells (female mid-concentration animal, H&E, x 500).

Although both squamous cell carcinomas and adenocarcinomas frequently invaded the subcutis, surrounding bones, vessels, nerve bundles, the cribriform plate and the cerebrum, metastases were seen in only 4 animals (3 top-concentration rats and one mid-concentration rat). Two adenocarcinomas

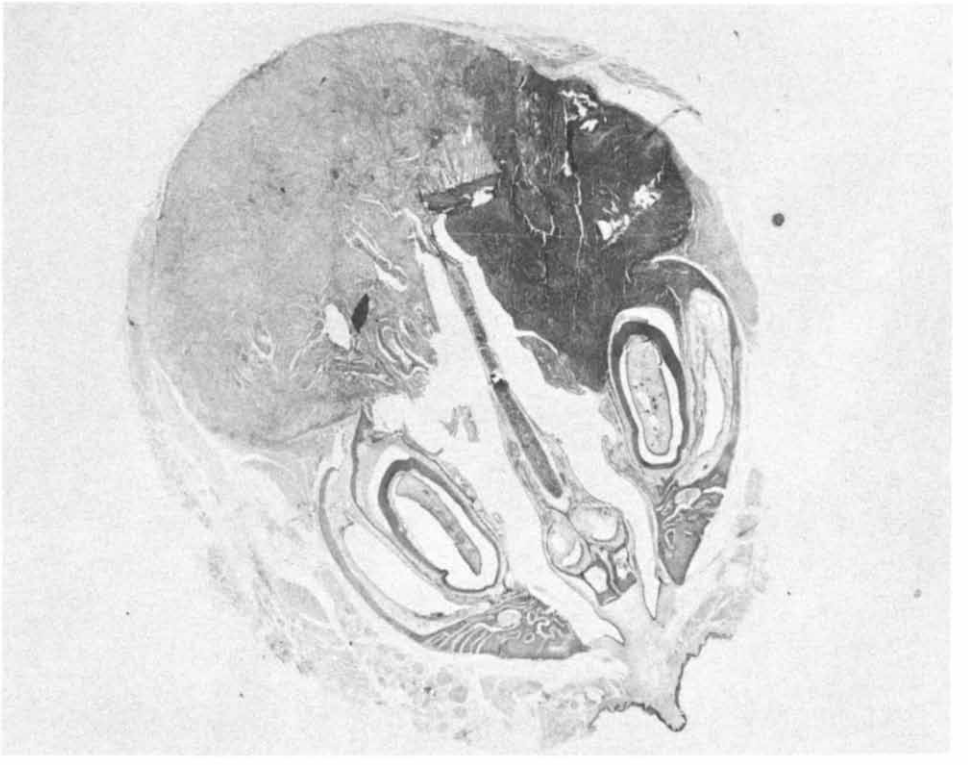

Fig. 5. Osteolytic adenocarcinoma growing into the subcutis and the olfactory lobe. Histologically the dark part of the tumour consists of densely packed small cells with little basophilic cytoplasm and huge hyperchromatic nuclei, whereas the light part consists of large cells with scant cytoplasm and round to ovoid, pale nuclei (male low-concentration animal, H&E, x 7.4).

had metastasized to cervical lymph nodes, and 1 adenocarcinoma and 1 squamous cell carcinoma to the lungs.

Outside the nose only 2 other neoplasms were found in the respiratory tract: 1 poorly differentiated adenocarcinoma in the lungs of a female low-concentration rat and 1 carcinoma in situ in the larynx of a female mid-concentration animal.

Neoplasms found in organs outside the respiratory tract all appeared to be common findings in rats of this strain and age, and were considered to be fortuitous findings unrelated to the acetaldehyde exposure.

DISCUSSION

From the present study it appeared that the nasal tumours induced by acetaldehyde can be distinguished into 2 major types: squamous cell carcinomas mainly derived from respiratory epithelium and adenocarcinomas from olfac-

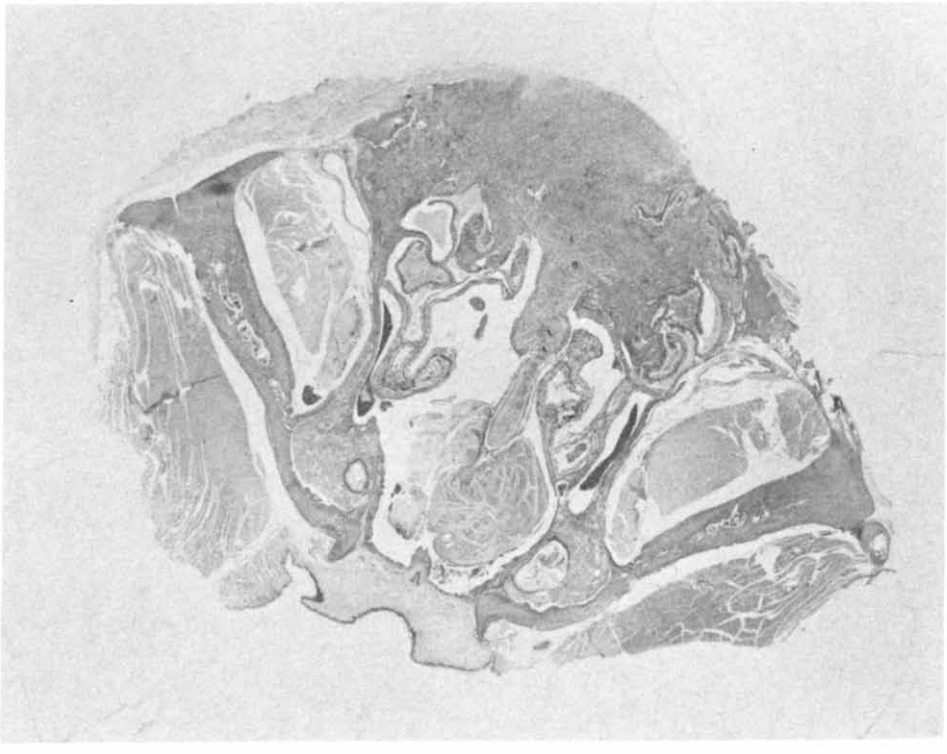

Fig. 6. Large nasal adenocarcinoma growing outside the nose and a small squamous cell carcinoma of the nasal septum (female top-concentration animal, H&E, x 7.1).

tory epithelium. Squamous cell carcinomas principally occurred in the mid- and top-concentration groups, their incidences being clearly dose-related. A nasal squamous carcinoma was also found in 1 male rat of the low-concentration group and in 1 male control rat. In the latter animals the tumours were associated with dystrophic, chronically inflamed incisor teeth. This condition of necrotising odontodystrophy is not uncommon in the strain of rats used. In a long term inhalation study with this strain of rats carried out in our laboratory, 3/99 males of the control group had developed a nasal squamous carcinoma, and each of the 3 animals also suffered from severe necrotising odontitis, periodontitis and rhinitis (P.G.J. Reuzel; pers. comm.). Therefore, the squamous cell carcinoma found in the low-concentration rat is considered a fortuitous finding unrelated to treatment. Adenocarcinomas were found in each of the test groups; no such nasal tumour was observed in controls. The incidence of adenocarcinomas was highest in the mid-concentration group (59/106), lowest in the low-concentration group (22/100), and in between in the top-concentration group (44/102). The relatively low incidence in the top-exposure group is most probably due to the high and relatively early mortality from causes other than nasal adenocarcinomas in this group. In addition to neoplas-

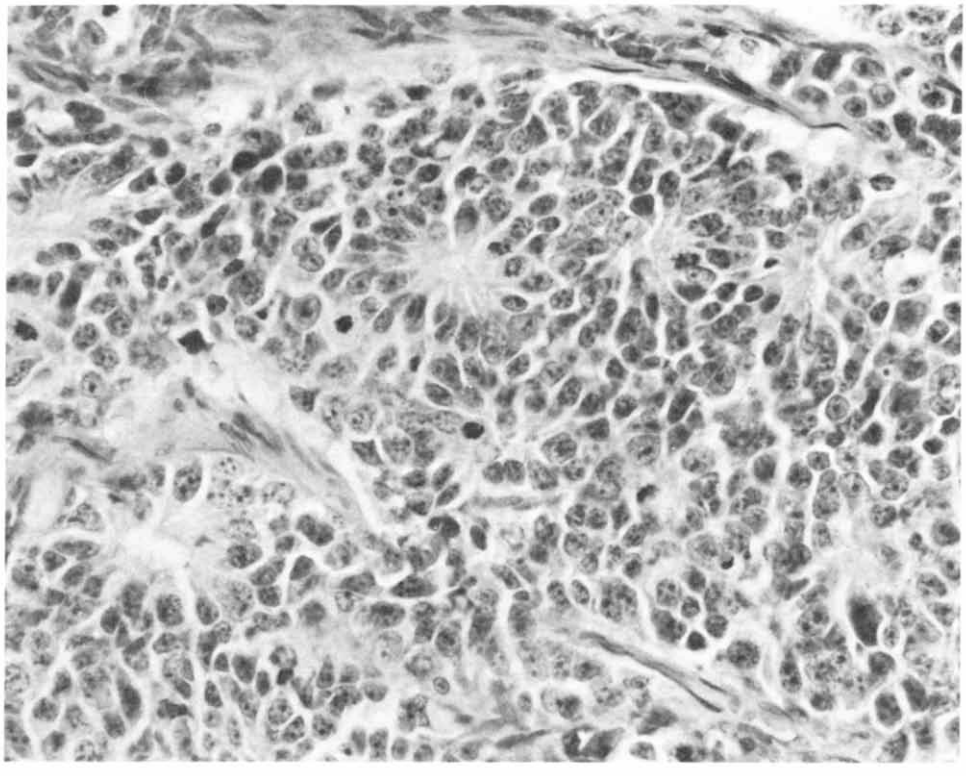

Fig. 7. Adenocarcinoma of the nasal olfactory epithelium, exhibiting rosettes and pseudorosettes (female mid-concentration animal, H&E, x 500).

tic lesions, exposure to acetaldehyde resulted in degenerative, hyperplastic and metaplastic changes in the nose [13], the most characteristic ones being: (a) hyperplasia and squamous metaplasia frequently accompanied by keratinisation and occasionally by cellular and nuclear atypia of the respiratory epithelium in mid- and top-concentration rats, and (b) basal cell hyperplasia of olfactory epithelium in the low- and mid-concentration groups.

These findings underline the previous preliminary conclusion that the olfactory epithelium is more susceptible to the cytotoxic action of acetaldehyde and/or is more heavily exposed to acetaldehyde than the respiratory epithelium [13]. These observations strongly support the hypothesis that the nasal tumours arise from epithelium which is damaged by acetaldehyde, viz. the olfactory epithelium in the low-concentration group and both the olfactory and the respiratory epithelium in the mid- and top-concentration groups [13]. This hypothesis is further supported by the results of a study into the recovery of acetaldehyde-induced nasal changes in rats [14]. These results showed that hyperplastic and metaplastic epithelial changes found in the nose of rats exposed to 1500 or 3000/1000 ppm acetaldehyde for 52 weeks were at least partly irreversible, and suggested that the irreversible alterations often

TABLE III

CUMULATIVE INCIDENCE OF NASAL TUMOURS IN RATS EXPOSED TO VARIOUS CONCENTRATIONS OF ACETALDEHYDE VAPOUR FOR AT MOST 28 MONTHS

Type of tumours	Incidence of tumours [a] after:																			
	12 months conc. group				16 months conc. group				20 months conc. group				24 months conc. group				28 months conc. group			
	Contr.	Low	Mid	Top	Contr.	Low	Mid	Top	Contr.	Low	Mid	Top	Contr.	Low	Mid	Top	Contr.	Low	Mid	Top
Males	(1)	(1)	(1)	(12)	(3)	(3)	(6)	(26)	(4)	(7)	(18)	(41)	(18)	(24)	(25)	(49)	(49)	(52)	(53)	(49)
Squamous cell carcinoma	0	0	1	0	1	0	2	5	1	0	2	11	1	1	3	16	1	1	10*	16***
Adenocarcinoma	0	1	0	0	0	3	3	8	0	3	13	17	0	8*	16***	21***	0	16***	31***	21***
Carcinoma in situ	0	0	0	0	0	0	0	1	0	0	0	1	0	0	0	1	0	0	0	1
Females	(0)	(1)	(1)	(8)	(1)	(1)	(5)	(25)	(4)	(6)	(11)	(34)	(8)	(15)	(23)	(53)	(50)	(48)	(53)	(53)
Squamous cell carcinoma	0	0	0	1	0	0	0	9	0	0	0	10	0	0	2	17	0	0	5	17***
Adenocarcinoma	0	0	1	0	0	0	5	4	0	2	11***	13	0	5	16**	23**	0	6*	28***	23***
Carcinoma in situ	0	0	0	1	0	0	0	3	0	0	0	3	0	0	0	5	0	0	3	5

[a] The number of noses examined is given in parentheses.
Statistics: Fisher Exact Test $*P < 0.05$, $**P < 0.01$, $***P < 0.001$.

progressed to a neoplasm within several months, despite the discontinuation of the acetaldehyde exposure.

The present results are in line with those of earlier studies with acetaldehyde in hamsters [6,7]. Inhalation exposure of hamsters to the 'maximum tolerated concentration' of acetaldehyde (2500 ppm gradually decreased to 1650 ppm) for 7 h/day and 5 days/week resulted in hyper- and metaplastic changes of the nasal epithelium, and 3 out of 52 hamsters developed a nasal tumour, i.e. 1 adenoma, 1 adenocarcinoma and 1 anaplastic carcinoma. However, the major tumour response occurred in the larynx: 11 out of 47 hamsters developed tumours of the laryngeal epithelium, whereas in the present study with rats only 1 carcinoma in situ was found in the larynx. This difference in tumour site between the 2 species may be due to differences in anatomy of the upper respiratory tract, breathing pattern, susceptibility of the lining epithelium or a combination of these factors [13].

Comparison of the nasal effects of acetaldehyde with those reported for formaldehyde [8—11] leads to the following conclusions: (a) high concentrations of acetaldehyde (2000 ppm and above) as well as of formaldehyde (14 ppm and above) are capable of damaging both the respiratory and the olfactory epithelium, (b) low effective concentrations of acetaldehyde (400—1000 ppm) only affect the olfactory epithelium while low effective concentrations of formaldehyde (2—3 ppm) only damage the respiratory epithelium indicating that the main impact of acetaldehyde occurs more in the posterior part of the nose than that of formaldehyde, and (c) acetaldehyde exposure leads to nasal squamous cell carcinomas and adenocarcinomas whereas formaldehyde almost exclusively induces nasal squamous cell carcinomas.

In the absence of a metabolic system acetaldehyde has been found to be not mutagenic to several strains of *Salmonella typhimurium* [15]. However, it was mutagenic to *Escherichia coli* and *Saccharomyces cerevisiae* [16]. From other studies it appeared that acetaldehyde induced sister chromatid exchanges [17,18] and chromosomal aberrations [19] in human peripheral lymphocytes in vitro. It also induced sister chromatid exchanges in bone marrow cells, peripheral lymphocytes and cultured ovary cells of Chinese hamsters [20—22]. Moreover, acetaldehyde has been found to induce cell transformation in C3H/10T1/2 cells [23] and micronuclei, chromosomal aberrations and aneuploidies in rat fibroblasts [24,25]. It is, therefore, reasonable to assume that acetaldehyde possesses initiating activity which may play a role in the induction of nasal tumours in rats and laryngeal tumours in hamsters. The genotoxicity and DNA-reactivity of formaldehyde has been shown in a wide variety of standard tests [26]. Therefore, both compounds most probably possess initiating activity. Both aldehydes also appeared to be able to induce nasal carcinomas in experimental animals, thus, meeting the widely accepted criteria for being classified as complete (genotoxic) carcinogens [27].

Exposure levels of both formaldehyde and acetaldehyde resulting in nasal carcinomas are very irritating and cause much damage to the nasal mucosa followed by regenerative hyperplasia and metaplasia. This process of recurrent tissue damage and repair is probably mainly responsible for the promoting

activity of these compounds. Since formaldehyde is known to react preferentially with single-stranded DNA and the incidence of dividing cells in the normal intact nasal epithelium is low, it seems reasonable to suppose that the initiating potential of formaldehyde (and probably also of acetaldehyde) in concentrations not leading to cell damage is very low. On the other hand, concentrations of these aldehydes causing recurrent tissue damage may be very effective with respect to initiation. Moreover, the increased cell turnover may strongly enhance the fixation of relevant DNA damage, and subsequently strongly increase the chance of progression of preneoplastic cells to cancer. As a consequence formaldehyde and acetaldehyde in subcytotoxic concentrations are likely to be very weak initiators (there are only a few dividing cells) with only minor, if any, promoting activity (there is no increased cell turnover) [28,29]. This means that in subcytotoxic concentrations these aldehydes most probably cannot act as complete carcinogens, but only as weak initiators. These considerations suggest that the cytotoxic effects of these aldehydes may be very important for the induction of nasal carcinomas in experimental animals [30]. In this respect the question arises as to how far exposure of human beings to subcytotoxic (actual exposure) concentrations of formaldehyde or acetaldehyde constitutes a carcinogenic risk. If there is a risk, it seems to be extremely low. On the other hand, the risk may be more substantial if such exposure takes place under conditions of recurrent tissue damage due to other factors [28,29].

In a recent publication on the interpretation and use of data from long-term carcinogenicity studies in animals, Swenberg [31] stressed the need for research programmes that will evaluate the role of cytotoxicity in carcinogenicity. This view is highly supported by the results of the present study.

Since nasal cancer is not a common type of cancer in man, one might question the relevance for man of untoward effects of compounds on the nasal mucosa of rodents. One should realize that human beings are more likely to inhale through the mouth than rodents which are obligatory nose breathers. Mouth breathing means bypassing filtration by the nasal passsages [32]. Rodents have highly developed tortuous nasal turbinates, while human beings have relatively small noses containing less complex turbinates [33]. The implication of these physiological and anatomical differences between rodents and man may be that the effects of aldehydes on the nose of rodents have predictive value for effects in man on more distal parts of the respiratory tract such as larynx, bronchi and lungs [28,29].

ACKNOWLEDGEMENTS

The authors thank Drs C.A. van der Heÿden (Head of the Laboratory for Carcinogenesis and Mutagenesis, National Institute of Public Health and Environmental Protection, Bilthoven, The Netherlands) for his competent help in designing the study and his expert advice during the conduct of the experiment. They are indebted to Drs A.W. van der Wielen (Ministry of Housing, Physical Planning and Environmental Protection, Leidschendam, The Netherlands) for critical review of the manuscript and valuable suggestions.

REFERENCES

1 H. Elmenhorst and Ch. Schultz, Flüchtige Inhaltstoffe des Tabakrauches. Die chemischen Bestandteile der Gas-Dampf-Phase. Beitr. Tabakforsch., 4 (1968) 90.
2 R. Guillerm, R. Badre and B. Vignon, Effets inhibitoires de la fumée de tabac sur l'activité ciliaire de l'épithélium respiratoire et nature des composants responsables. Bull. Acad. Natl. Med. (Paris), 145 (1961) 416.
3 J.R. Newsome, V. Norman and Ch. Keith, Vapour phase analysis of tobacco smoke. Tob. Sci., 9 (1965) 102.
4 D.M. Pace and A. Elliot, Studies on the effects of acetaldehyde in tissue cells cultivated in vitro. Cancer Res., 20 (1960) 868.
5 A. Kruysse, V.J. Feron and H.P. Til, Repeated exposure to acetaldehyde vapour. Studies in Syrian golden hamsters. Arch. Environ. Health, 30 (1975) 449.
6 V.J. Feron, Effects of exposure to acetaldehyde in Syrian hamsters simultaneously treated with benzo(*a*)pyrene or diethylnitrosamine. Prog. Exp. Tumor res., 24 (1979) 162.
7 V.J. Feron, A. Kruysse and R.A. Woutersen, Respiratory tract tumours in hamsters exposed to acetaldehyde vapour alone or simultaneously to benzo(*a*)pyrene or diethylnitrosamine. Eur. J. Cancer Clin. Oncol., 18 (1982) 13.
8 J.A. Swenberg, W.D. Kerns, R.I. Mitchell, E.J. Gralla and K.L. Pavkov, Induction of squamous cell carcinomas of the rat nasal cavity by inhalation exposure to formaldehyde vapour. Cancer Res., 40 (1980) 3398.
9 Battelle Columbus Laboratories, Final report on a chronic inhalation toxicity study in rats and mice exposed to formaldehyde. Final report. CIIT, docket 10922, December 31, 1981, p. 173.
10 R.E. Albert, A.R. Sellakumar, S. Laskin, M. Kuschner, N. Nelson and C.A. Snyder, Gaseous formaldehyde and hydrogen chloride induction of nasal cancer in the rat. J. Natl. Cancer Inst., 68 (1982) 547.
11 W.D. Kerns, K.L. Pavkov, D.J. Donofrio, E.J. Gralla and J.A. Swenberg, Carcinogenicity of formaldehyde in rats and mice after long-term inhalation exposure. Cancer Res., 43 (1983) 4382.
12 L.M. Appelman, R.A. Woutersen and V.J. Feron, Inhalation toxicity of acetaldehyde in rats. I. Acute and subacute studies. Toxicology, 23 (1982) 293.
13 R.A. Woutersen, L.M. Appelman, V.J. Feron and C.A. van der Heijden, Inhalation toxicity of acetaldehyde in rats. II. Carcinogenicity study: interim results after 15 months. Toxicology, 31 (1984) 123.
14 R.A. Woutersen and L.M. Appelman, Life-span inhalation carcinogenicity study of acetaldehyde in rats: III. Recovery after 52 weeks of exposure. CIVO-report no. V. 84.288, 1984, CIVO-Institutes TNO, Zeist, The Netherlands.
15 H.S. Rosenkranz, Mutagenicity of halogenated alkanes and their derivatives. Environ. Health Perspect., 21 (1977) 798.
16 P.V. Veghelyi, M. Osztovics, G. Kardos, L. Leisztner, E. Szaszovszky, S. Igali and J. Imprei, The fetal alcohol syndrome: symptoms and pathogenesis. Acta. Pediat. Acad. Sci. Hung., 3 (1978) 171.
17 T. Jansson, The frequency of sister chromatid exchanges in human lymphocytes treated with ethanol and acetaldehyde. Hereditas, 97 (1982) 301.
18 H. Ristow and G. Obe, Acetaldehyde induces cross-links in DNA and causes sister-chromatid exchanges in human cells. Mutat. Res., 58 (1978) 115.
19 G. Obe, A.T. Natarajan, M. Meyers and A. Den Hertog, Induction of chromosomal aberrations in peripheral lymphocytes of human blood in vitro, and of SCEs in bone-marrow cells of mice in vivo by ethanol and its metabolite acetaldehyde. Mutat. Res., 68 (1979) 291.
20 G. Obe and B. Beek, Mutagenic activity of aldehydes. Drug Alcohol Depend., 4 (1979) 91.
21 A. Korte, G. Obe, I. Ingwersen and G. Ruckert, Influence of chronic ethanol uptake and acute acetaldehyde treatment on the chromosomes of bone-marrow cells and peripheral lymphocytes of Chinese hamsters. Mutat. Res., 88 (1981) 389.
22 W.K. de Raat, P.B. Davis and G.L. Bakker, Induction of sister-chromatid exchanges by alcohol and alcoholic beverages after metabolic activation by rat-liver homogenate. Mutat. Res., 124 (1983) 85.

23 D.J. Abernethy, J.H. Frazelle and C.J. Boreiko, Effects of ethanol, acetaldehyde and acetic acid in the C3H/10T1/2 C18 cell transformation system. Environ. Mutagen., 4 (1982) 331 (abstract).
24 R.P. Bird and H.H. Draper, Effect of malonaldehyde and acetaldehyde on cultured mammalian cells: growth, morphology and synthesis of macromolecules. J. Toxicol. Environ. Health, 6 (1980) 811.
25 R.P. Bird, H.H. Draper and P.K. Basrur, Effect of malonaldehyde and acetaldehyde on cultured mammalian cells. Production of micronuclei and chromosomal aberrations. Mutat. Res., 101 (1982) 237.
26 H. d'A Heck and M. Casanova-Schmitz, Biochemical toxicology of formaldehyde. Rev. Biochem. Toxicol., 6 (1984) 155.
27 J.H. Weisburger and G.M. Williams, The decision-point approach for systematic carcinogen testing. Food Cosmet. Toxicol., 19 (1981) 561.
28 V.J. Feron, R.A. Woutersen and L.M. Appelman, Epithelial damage and tumours of the nose after exposure to four different aldehydes by inhalation, in P. Grosdanoff, R. Bass, U. Hackenberg, D. Henschler, D. Muller and H.-J. Klimisch (Eds.), Problems of Inhalatory Toxicity Studies, MMV Medizin Verlag Munchen, 1984, p. 587.
29 V.J. Feron, R.A. Woutersen and B.J. Spit, Pathology of chronic nasal toxic responses including cancer, in C.S. Barrow (Ed.), Toxicology of the nasal passages, Hemisphere Publishers Inc., Washington, Dc, 1986, p. 67.
30 R. Griesemer, C. Boreiko, F.J. de Serres, V.J. Feron, J.J. McCormick, J.A. Swenberg, B.F. Trump, A. Upton and J. Ward, Consensus workshop on formaldehyde: carcinogenicity/histopathology/genotoxicity panel report. Environ. Health Perspect., 58 (1985) 340.
31 J.A. Swenberg, The interpretation and use of data from long-term carcinogenesis studies in animals. CIIT-activities, 5 (1985) 1.
32 N.P. Page, Concepts of bioassay program in environmental carcinogenesis, in H. Kraybill and H. Mehlman (Eds.), Environmental Carcinogenesis, Hemisphere Publishers Inc., Washington D.C., 1977, p. 87.
33 D.F. Proctor and J.C.F. Chang, Comparative anatomy and physiology of the nasal cavity, in G. Reznik and S.F. Stinson (Eds.), Nasal Tumors in Animals and Man I. Anatomy, Physiology and Epidemiology, CRC Press Inc., Boca Raton, Florida, 1983, p. 1.